



## Data Article

# Sagittal cranial projections dataset extracted from CBCT volumes corrected to natural head position in a mixed ethnicity population



Carlos Andrés Ferro Sánchez<sup>a,\*</sup>, Cristian Orlando Diaz Laverde<sup>b</sup>,  
Sandra Esperanza Nope Rodríguez<sup>c</sup>, Juan Fernando Aristizábal<sup>b</sup>,  
Oscar Iván Campo Salazar<sup>a</sup>

<sup>a</sup> Faculty of Engineering, Universidad Autónoma de Occidente, Cali, Colombia

<sup>b</sup> Health Faculty, Universidad del Valle, Cali, Colombia

<sup>c</sup> Escuela de Ingeniería Eléctrica y Electrónica (EIEE), Facultad de Ingeniería, Universidad del Valle, Colombia

## ARTICLE INFO

*Article history:*

Received 21 May 2024

Revised 31 May 2024

Accepted 4 June 2024

Available online 18 June 2024

Dataset link: [Sagittal Image Dataset Corrected to Natural Head Position from a Mixed Ethnicity Population. \(Original data\)](#)

*Keywords:*

Cephalometric

Craniofacial morphology

Orthodontic diagnosis

Data analysis

Images of mestizo population

## ABSTRACT

This dataset features 200 sagittal projection images derived from Cone Beam Computed Tomography (CBCT) scans, corrected according to the Natural Head Position (NHP) guidelines proposed by Fredrik Lundström and Anders Lundström. The images originate from orthodontic patients in Cali, Valle del Cauca, Colombia, encompassing both initial phases and ongoing treatments. The dataset is divided into two groups: 100 images from female subjects (CoF) and 100 from male subjects (CoM), facilitating gender-specific studies.

The dataset is accompanied by an Excel file "Data info.xlsx" that details the rotation angles in the axial (Yaw), coronal (Roll), and sagittal (Pitch) planes, along with the pixel size and image dimensions. This detailed documentation supports the replication of studies and aids in the interpretation of cephalometric analyses.

Corrections made to align the images with NHP standards involve adjustments in the three main anatomical planes using points from the frontozygomatic suture (Fz) in the

\* Corresponding author.

E-mail address: [cferro@uao.edu.co](mailto:cferro@uao.edu.co) (C.A.F. Sánchez).

axial and coronal planes, and sella (S) and nasion (N) for the sagittal plane.

© 2024 The Author(s). Published by Elsevier Inc.

This is an open access article under the CC BY-NC license (<http://creativecommons.org/licenses/by-nc/4.0/>)

## Specifications Table

Subject	Biomedical Engineering; Bioengineering; Dentistry, Oral Surgery and Medicine; Medical Imaging.
Specific subject area	Health and Medical Sciences; Medical Imaging; Cephalometric Analysis; Craniofacial Morphology.
Type of data	Images (.jpg), Table (.xlsx).
Data collection	Data were collected using two CBCT machines. CBCT1 (Imaging Science International) Model 17/19 with settings: 120 kV, 5 mA; CBCT2 (NNT) Model NNTVGI MK4 with settings: 110 kV, 1 mA. Both were set for a full-face FOV with a slice thickness and slice increment of maximum 0.4 mm. Images were corrected for Yaw, Roll and Pitch according to NCP guidelines and validated by orthodontic specialists. Two hundred cone beam computed tomography (CBCT) images of the skull were taken from patients in Cali, Valle del Cauca, Colombia, who are initiating or already undergoing orthodontic treatment. These images were corrected to the natural head position and subsequently an X-ray summation projection in the sagittal plane was extracted. The data set includes one hundred projections of female subjects, identified with the acronym CoF, and one hundred of male subjects, identified with the acronym CoM.
Data source location	Cali, Valle del Cauca, Colombia.
Data accessibility	Repository name: Mendeley Data identification number: <a href="https://doi.org/10.17632/3hctm4nsjy.1">doi:10.17632/3hctm4nsjy.1</a> Direct URL to data: <a href="https://data.mendeley.com/datasets/3hctm4nsjy/1">https://data.mendeley.com/datasets/3hctm4nsjy/1</a>
Related research article	None

## 1. Value of the Data

- This dataset offers a standardized series of sagittal head images obtained through CBCT, corrected for Pitch, Yaw, and Roll according to established Natural Head Position (NHP) parameters.
- It provides educational material for teaching the interpretation of sagittal images and treatment planning, helping students understand the complexities of facial and cranial structures from a sagittal perspective in orthodontics and maxillofacial surgery.
- It can be used in studies requiring a precise understanding of sagittal cranial anatomy, allowing detailed analyses of post-correction craniofacial morphology.
- It can be used in the development and validation of diagnostic tools from cephalometric measurements derived from sagittal view images, particularly in the development of automatic segmentation algorithms, and the estimation of anatomical features from sagittal projections.

## 2. Background

Correcting the Natural Head Position (NHP) is essential in cephalometric studies to obtain precise measurements in profile radiographs, which are crucial in various branches of dentistry such as orthodontics and maxillofacial surgery [1–3]. Variations in head orientation can alter key measurements such as mandibular length, anterior facial height, and the sagittal relationship

between the jaws, directly impacting diagnostic and therapeutic decisions. Incorrect orientation can simulate conditions such as maxillary or mandibular protrusion or retrusion, leading to misdiagnoses and inappropriate treatments [4–8]. Therefore, using NHP as a reference is vital to ensure that the measurements accurately reflect the patient’s dentofacial morphology and provide a solid foundation for effective clinical interventions [9].

## 2.1. Data description

This dataset consists of 200 sagittal projections extracted from Cone Beam Computed Tomography (CBCT) images, meticulously corrected across three anatomical planes: Yaw (sagittal), Roll (coronal), and Pitch (sagittal). The corrections are based on the Natural Head Position (NHP) standards suggested by Fredrik Lundström and Anders Lundström [1,2].

## 2.2. Dataset Structure

- **Main Folders:** The dataset is organized in a main directory within the data repository named “Data”, which contains 200 images of male and female individuals, respectively, ensuring equitable representation.

## 2.3. Technical details

- **Image Format and Resolution:** All images are in JPG format, with resolutions ranging from 512×507 to 768×576 pixels. This allows for precise linear measurements, which are essential for detailed cephalometric analysis and morphological evaluations.
- **Pixel Dimensions and Size:** Pixel sizes vary between 0.25 mm and 0.4 mm, adapting to precision requirements for each type of analysis.

## 2.4. Supplementary data

- **Corrections Excel File:** The “Data info.xlsx” file documents the correction angles in Yaw, Roll, and Pitch for each JPG image, along with the pixel size, and dimensions of each image, as detailed in Table 1, providing crucial data for understanding and replicating the applied corrections.

**Table 1**

Example of data layout.

Ref_patient	Yaw	Roll	Pitch	Pixel size	Width	Height
CoF000_pos	3.69	2.21	2.75	0.3	512	507
CoM044_pos	-2.18	-2.05	10.42	0.25	640	543

## 2.5. Accessibility and usage

- **Availability and Applications:** The dataset is designed to be broadly accessible to researchers, academics, and professionals in fields such as orthodontics, radiology, and maxillofacial surgery. This collection offers a standardized and precise base for research, clinical practices, and technological developments in medical diagnosis and treatment.

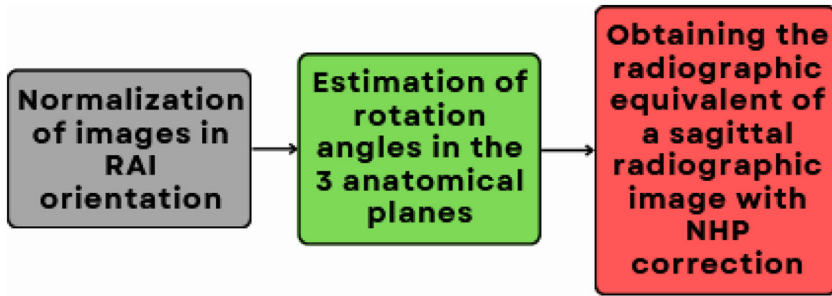


Fig. 1. General block diagram for natural head position (NHP) correction.

### 3. Experimental Design, Materials and Methods

#### 3.1. Materials

In this study, two cone beam computed tomography (CBCT) machines were used to acquire high-resolution images of the craniofacial structure. The first device was an Imaging Science International model 17/19, and the second device used was an NNT/NTVGiMK4.

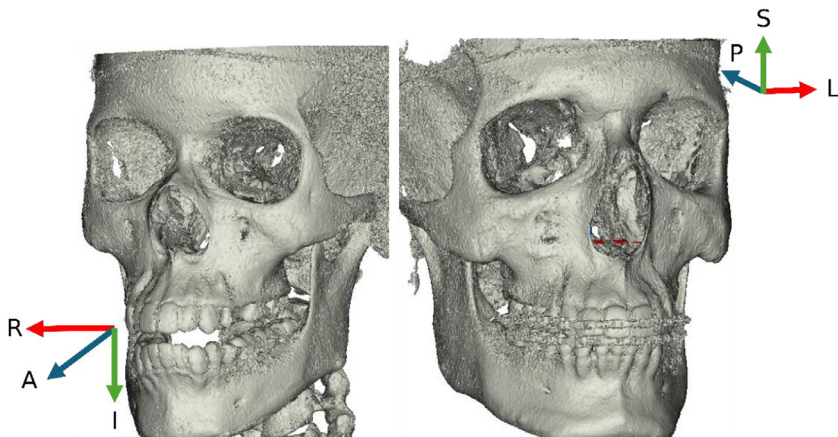
#### 3.2. Methods

This study focuses on developing a database of sagittal images, adjusted to the Natural Head Position (NHP), from CBCT images of individuals with mixed ethnic characteristics from Cali, Colombia. To ensure the NHP correction, the three steps shown in Fig. 1 were implemented.

This study addresses the correction of Natural Head Position (NHP) using CBCT images, for which a database of 200 CBCT images of patients from Cali, Colombia was compiled. The sample was approved by the research ethics committee of the Universidad Autónoma de Occidente, with ETHICS COMMITTEE ACT No. 01-2024 dated February 12, 2024.

For the creation of this corrected sagittal image database, a systematic approach was followed in three essential stages, aligned with the descriptive blocks of the provided diagram:

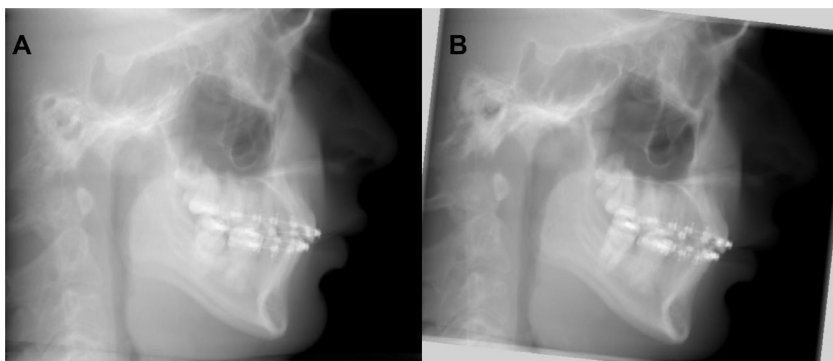
- 1. Normalization of images in RAI orientation:** Initially, the sequence of slices within the CBCT volume was organized using DICOM metadata for patient image orientation (IOP) and patient image position (IPP) [10]. Once the images are reorganized, they are normalized in RAI orientation, meaning the head orientation is directed from right to left, anterior to posterior, and from inferior to superior, providing a uniform base essential for subsequent analysis. In Fig. 2, the image on the left details the RAI orientation where the first slice is located in the lower or basal area, and it increases upwards, and the image on the right describes the LPS orientation (from left to right, posterior to anterior, and from superior to inferior), where the first slice of this volume starts at the top and increases downwards.
- 2. Estimation of rotation angles in the three anatomical planes:** This phase begins with the selection of anatomical references that exhibit minimal asymmetry among patients, to standardize measurements of rotation angles. For the axial plane, the angle is calculated between a horizontal line and the slope of the line drawn by connecting the most external points on the right and left sides of the frontozygomatic sutures (Fz) [11–13].
- 3. In the coronal plane,** the angle is calculated between a horizontal reference line and the line that connects the centroids of the ocular cavities [11,12,14].
- 4. In the sagittal plane,** the angle is calculated between a horizontal line passing through the cephalometric point of the sella (s), and the slope formed by connecting the cephalometric points of Sella (s) and nasion (N). However, in this case, the pitch rotation angle, following



**Fig. 2.** Head orientation coordinate systems. Left - RAI (Right Anteroinferior), and right - LPS (Left PosteroSuperior).

the recommendation by Fredrik Lundström and Anders Lundström [2], is set to  $3.8^\circ$  for men and  $4.1^\circ$  for women.

**Obtaining the radiographic equivalent of a sagittal radiographic image with NHP correction:** After correcting the rotations on the CBCT volume, an equivalent radiographic image is obtained by summing the slices in the sagittal plane [11]. Fig. 3 presents an example of the radiographic image: The uncorrected projection is depicted in Image A, while the sagittal projection has been corrected in three planes in Image B. This correction enhances the diagnostic accuracy of craniofacial structures by accurately aligning the head position in accordance with the Natural Head Position (NHP) method.



**Fig. 3.** X-ray summary projections in the sagittal plane from. (A) Original tomography, B) Natural head position correction tomography (NHP).

## Limitations

The database of images corrected in the natural position of the head has limitations regarding the ethnicity and age of the population, which corresponded to Colombian adults of mestizo ethnicity, specifically from the city of Cali, Valle del Cauca. This sample does not have a uniform distribution between patients of Afro-Colombian and mestizo ethnicity, nor of patients who do

or do not receive orthodontic treatment. These limitations may influence the generalizability of the results to other populations with different ethnic characteristics or orthodontic treatment status.

## Ethics Statement

During the data collection of this study, strict ethical considerations were followed:

- Patients' consent was obtained prior to the acquisition of the images, and no personal information was included in the records.
- To ensure patient anonymity, all personally identifiable information was removed from the images.
- Additionally, the study was approved by the Ethics Committee of the Universidad Autónoma de Occidente under ETHICS COMMITTEE ACT No. 01-2024 of February 12, 2024, thereby ensuring compliance with current ethical standards in medical research.
- The collection of these images was conducted in accordance with the Declaration of Helsinki issued by the World Medical Association.

## Data Availability

[Sagittal Image Dataset Corrected to Natural Head Position from a Mixed Ethnicity Population. \(Original data\)](#) (Mendeley Data).

## CRediT Author Statement

**Carlos Andrés Ferro Sánchez:** Conceptualization, Methodology, Software, Investigation, Writing – original draft, Visualization, Supervision; **Cristian Orlando Díaz Laverde:** Methodology, Validation, Investigation, Writing – original draft; **Sandra Esperanza Nope Rodríguez:** Software, Methodology, Writing – review & editing; **Juan Fernando Aristizábal:** Validation; **Oscar Iván Campo Salazar:** Writing – original draft.

## Acknowledgments

This research did not receive any specific grant from funding agencies in the public, commercial, or not-for-profit sectors.

## Declaration of Competing Interest

The authors declare that they have no known competing financial interests or personal relationships that could have appeared to influence the work reported in this paper.

## References

- [1] A. Lundström, F. Lundström, L.M.L. Lebet, C.F.A. Moorrees, Natural head position and natural head orientation: basic considerations in cephalometric analysis and research, *Eur J Orthod* 17 (2) (1995) 111–120, doi:[10.1093/EJO/17.2.111](https://doi.org/10.1093/EJO/17.2.111).
- [2] F. Lundström, A. Lundström, Natural head position as a basis for cephalometric analysis, *Am. J. Orthod. Dentofac. Orthop.* 101 (3) (1992) 244–247, doi:[10.1016/0889-5406\(92\)70093-P](https://doi.org/10.1016/0889-5406(92)70093-P).
- [3] N. Bansal, J. Singla, G. Gera, M. Gupta, G. Kaur, Reliability of natural head position in orthodontic diagnosis: a cephalometric study, *Contemp. Clin. Dent.* 3 (2) (2012) 180, doi:[10.4103/0976-237X.96824](https://doi.org/10.4103/0976-237X.96824).
- [4] F. Lundström, A. Lundström, Natural head position as a basis for cephalometric analysis, *Am. J. Orthod. Dentofac. Orthop.* 101 (3) (1992) 244–247, doi:[10.1016/0889-5406\(92\)70093-P](https://doi.org/10.1016/0889-5406(92)70093-P).

- [5] D.M. Ramírez, J. Canseco Jiménez, E. González Ramírez, H. Jaramillo Paniagua, V. Cuairán Ruidíaz, Discrepancies in cephalometric measurements in relation to natural head position, *Rev. Mex. Ortod.* 1 (1) (2013) e27–e32, doi:[10.1016/S2395-9215\(16\)30117-9](https://doi.org/10.1016/S2395-9215(16)30117-9).
- [6] R.K.W. Schulze, L.K.M. Linnerth, Vertical head rotation as major source of differences between time-separated digital cephalometric radiographs of patients acquired in one cephalostat X-ray device, *BMC Med. Imaging* 22 (1) (2022) 1–10, doi:[10.1186/S12880-022-00935-X/FIGURES/5](https://doi.org/10.1186/S12880-022-00935-X/FIGURES/5).
- [7] A. Shokri, A. Miresmaeili, N. Farhadian, S. Falah-Kooshki, P. Amini, N. Mollaie, Effect of changing the head position on accuracy of transverse measurements of the maxillofacial region made on cone beam computed tomography and conventional posterior-anterior cephalograms, *Dentomaxillofacial Radiol.* 46 (2017), doi:[10.1259/dmfr.20160180](https://doi.org/10.1259/dmfr.20160180).
- [8] S. Malkoc, Z. Sari, S. Usumeze, A.E. Koyuturk, The effect of head rotation on cephalometric radiographs, *Eur. J. Orthod.* 27 (2005) 315–321, doi:[10.1093/ejo/cjh098](https://doi.org/10.1093/ejo/cjh098).
- [9] H. Stephens, *Comparison of facial midline landmark and condylar position changes following orthognathic surgery*, Master's Thesis, University of Southern California, 2017.
- [10] D. Atkinson, *Geometry in Medical Imaging: DICOM and NIFTI formats*, 2022, doi:[10.5281/zenodo.6467772](https://doi.org/10.5281/zenodo.6467772).
- [11] M. Prokop, M. Galanski, A.J. van der Molen, C. Schaefer-Prokop, *Spiral and Multislice Computed Tomography of the Body*, Thieme, Stuttgart, Germany, 2001.